

# Tunica Albuginea Underlap—A New Modification of the Nesbit Procedure: Description of the Technique and Preliminary Results

J. Ullrich Schwarzer, MD, PhD\*† and Heiko Steinfatt, MD\*†

\*Andrologie Centrum München, München, Germany; †Department of Urology, Chirurgische Klinik München-Bogenhausen, München, Germany

DOI: 10.1111/j.1743-6109.2012.02887.x

## ABSTRACT

**Introduction.** We describe a new surgical technique for the treatment of penile curvature that combines features of the Nesbit procedure with features of tunical plication. U-shaped flaps of tunica albuginea are freed from the corpus cavernosum. The flaps are brought under the remaining tunica albuginea and are fixated with single absorbable sutures. As the defects of the tunica are sealed tightly and with high tensile strength by double layers of tunica albuginea, correction of the abnormal curvature is achieved.

**Aim.** To present our experience with a new surgical technique for the treatment of penile curvature.

**Methods.** Between 2008 and 2011, 50 patients underwent the underlap technique because of Peyronie's disease (37) or congenital penile deviation (13) in a single center.

**Main Outcome Measures.** Preoperative and postoperative evaluation included the Erection Hardness Score (EHS) and the Symptom Score for Induratio penis plastica (IPP-SSC), a symptom score for penile deviation that was based on a consensus of regional andrologists. Clinical data concerning the early postoperative outcome were analyzed retrospectively using standardized items.

**Results.** Mean age  $\pm$  standard deviation was  $59.7 \pm 8.4$  years for patients with Peyronie's disease and  $34.1 \pm 7.8$  years for patients with congenital penile deviation. The mean follow-up period was 27 months. The major complication rate was 4%, overall satisfaction 86%. Intraoperative correction of the curvature was achieved in 100%, significant relapse occurred in 6%. The mean difference of preoperative and postoperative IPP-SSC was 8.1 (95% confidence interval [CI] 7.24 to 8.96). The mean difference of preoperative and postoperative EHC was  $-0.03$  (95% CI  $-0.16$  to  $0.09$ ).

**Conclusions.** Preliminary results obtained with the underlap technique showed promising outcome with minimal morbidity. The new technique might have three main advantages: more flexible intraoperative correctability of the curvature, tighter sealing of the tunical defects, and greater tensile strength of the plications. **Schwarzer JU and Steinfatt H. Tunica albuginea underlap—A new modification of the Nesbit procedure: Description of the technique and preliminary results. J Sex Med \*\*;\*\*:\*\*\_\*\*.**

**Key Words.** Penile Deviation; Tunica Albuginea; Nesbit Procedure; Peyronie's Disease

## Introduction

Several techniques for the correction of congenital and acquired deviation of the penis have been described. Reconstructive surgical treatment for penile deviation is composed of either lengthening the concave side (incision and grafting) or shortening the convex side of the penis (Nesbit procedure or plication techniques) [1–4].

The classical procedure to shorten the convex side of the penis by excision of ellipsoids of tunica

albuginea was initially described by Nesbit [5]. Incision techniques in a Heineke–Mikulicz fashion have been proposed [4]. Plication techniques that avoid the excision of tunica albuginea might offer a less invasive approach to correct penile deviation [6,7].

There are no prospective randomized trials comparing the different methods. In a larger retrospective series with 175 patients, better correction of the curvature was achieved with the Nesbit procedure than with a plication technique [8].

Another study reported a higher number of relapses after plication as compared with the Nesbit procedure, most likely due to insufficient tensile strength of the plications [8,9].

### Aims

We present our experience with a new surgical technique for the treatment of penile curvature that combines elements of the original Nesbit procedure with features of tunical plication techniques.

### Methods

#### Patient Population

Between 2008 and 2011, 50 patients underwent the modified Nesbit procedure. Thirty-seven patients were operated due to Peyronie's disease (IPP) and 13 patients due to congenital penile deviation (CPD). All patients had penile deviation of 30 degrees or more, sufficient erectile function, absence of a narrowing deformity, and adequate penile length. In patients with IPP, stable disease had been present for at least 6 months. If these criteria were not met, surgery was deferred or a more suitable alternative technique was performed, e.g., tunica albuginea free grafting from proximal corpus cavernosum [10] or other grafting techniques.

#### Surgical Technique

In all patients, the sleeve technique with circumcision was carried out. The deviation was assessed by artificial erection, and in the area of maximal curvature, Buck's and Colles' fascia was cut through longitudinally to the penis shaft. If necessary, the dorsal neurovascular bundle and the corpus spongiosum were meticulously mobilized using magnifying glasses. The appropriate sites needed to straighten the penis were determined with Allis clamps (Aesculap AG, Tuttlingen, Germany).

In contrast to the Nesbit technique, flaps of tunica albuginea were freed from the underlying corpus cavernosum after U-shaped incisions and no tunical tissue was removed. Underlapping these flaps under the remaining tunica albuginea and watertight fixation of the doubled tunical layer with interrupted synthetic absorbable sutures (polyglactin 1-0 and 3-0) leads to the correction of the abnormal curvature.

Colles' and Buck's fascia and penile skin were closed in layers with single absorbable sutures, and a moderately compressive dressing was applied (Figures 1 and 2).

### Main Outcome Measures

#### Collection of Clinical Data

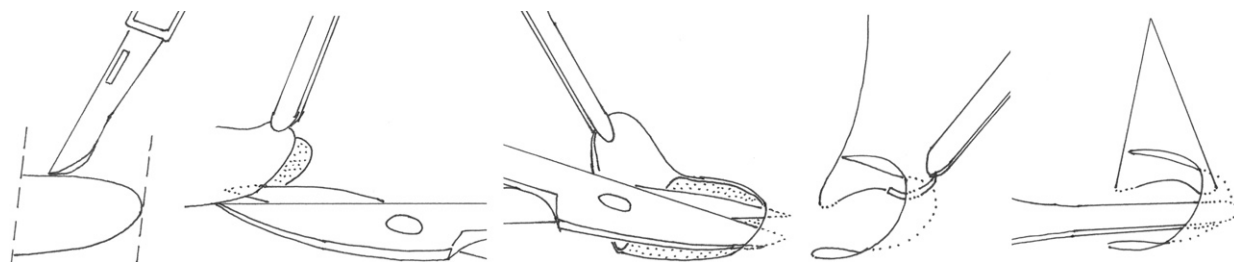
Medical records were retrospectively reviewed. Patient data were collected in a dedicated database using the following items: age, degree and direction of deviation, diagnosis, early postoperative complications (infection, hematoma, neurological impairment, other), and amount of correction.

#### Preoperative and Postoperative Symptom Scores

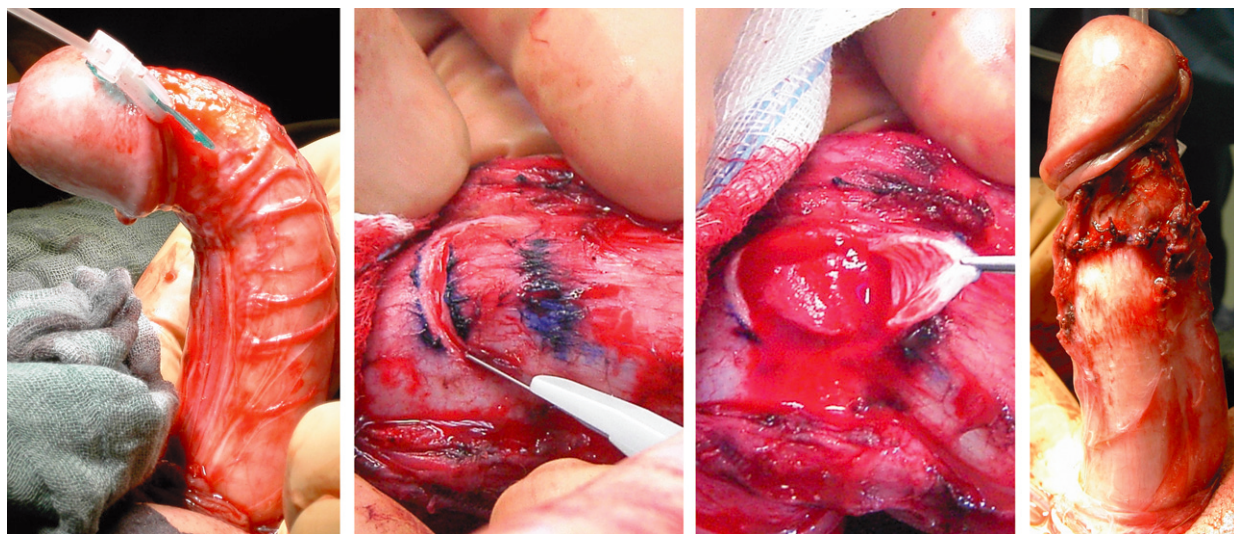
Erectile function was assessed on a scale from 0 to 4 according to the Erection Hardness Score (EHS) preoperatively and during follow-up [11]. A symptom score for IPP that had been established by a consensus of regional andrologists in 2006 was used preoperatively and during follow-up (see Table 1). Each item of Table 1 had to be rated by the patients on a scale from 0 to 4 (not at all, some, moderate, strong, very strong). The values were summed up to form the IPP-SSC. Preoperative IPP-SSC and IPP-SSC of the long-term follow-up were compared using the paired *t*-test.

#### Therapy-Related Outcome and Patient Satisfaction

Therapy-associated outcome and patient satisfaction during follow-up were evaluated on the basis



**Figure 1** Creating the tunica underlap.



**Figure 2** Intraoperative site

of a previously described questionnaire [12]. The patients had to rate the following therapy-related items on a scale from 0 to 4 (not at all, some, moderate, strong, very strong): relapse, shortening, neurological impairment, indurations, and worsening of erectile function, as well as overall satisfaction and improvement of quality of life. In case of relapse, the amount or degree was also requested.

## Results

Patient characteristics are shown in Table 2.

Table 3 summarizes early postoperative outcomes. Long-term outcomes and overall satisfaction can be seen in Table 4.

In the subgroup of patients with CPD, satisfaction was 80% very strong and 20% strong. There was no significant relapse in the CPD group. Also, there was no complaint in the CPD group concerning the shortening of the penis as well as concerning worsened erectile dysfunction (ED).

Table 5 compares preoperative and postoperative symptom scores (EHS and IPP-SSC). The

mean of the preoperative IPP-SSC minus the IPP-SSC of the long-term follow-up is 8.1 (95% confidence interval [CI] 7.24 to 8.96). The two-tailed *P* value is less than 0.0001. The mean of the preoperative EHS minus the EHS of the long-term follow-up is  $-0.03$  (95% CI  $-0.16$  to  $0.09$ ). The two-tailed *P* value = 0.57.

**Table 1** Symptom score for IPP (IPP-SSC)

Impairment	Scale
Due to deviation	0–4
Due to indurations	0–4
Due to pain	0–4
Due to shortening	0–4
Of overall sex life due to IPP	0–4
IPP-SSC (sum of 1. to 5.)	0–20

**Table 2** Patient characteristics

Characteristics		Standard deviation
Patients with congenital penile deviation		
Number	13	
Mean age (year)	34.1	7.8
Patients with IPP		
Number	37	
Mean age (year)	59.7	8.4
Mean deviation (degree)		
Dorsal/ventral	60	22.8
Left/right	12	17.5
Torsion	8	19.6
Mean number of underlaps	2.9	1.5

**Table 3** Early postoperative outcome

Early postoperative outcome	N (%)
Correction of deviation	50 (100)
Minor complications	
Wound infection	1 (2)
Hematoma	4 (8)
Neurological impairment	1 (2)
Major comp. requiring surgical revision	
Hematoma	1 (2)
Paraphimosis	1 (2)

**Table 4** Long-term outcome and satisfaction (mean follow-up 23 months, follow-up rate 78%)

Long-term outcome and satisfaction		
	%	
Satisfaction	87	72% very strong, 15% strong, 13% else
Relapse	6	3% strong (>45°), 3% medium (>15°), 20% some (<15°), 73% not at all
Shortening	78	21% not at all, 65% some, 13% medium
Neurological Impairment	4	4% some, 96% not at all
Indurations	4	4% some, 96 not at all
Worsened ED	13	13% some, 87% not at all

**Table 5** Comparison of preoperative symptom scores and symptom scores of the long-term follow-up (mean follow-up 23 months, follow-up rate 78%)

	Score (mean, standard deviation)	P
Preoperative EHS	2.97, 0.63	
Postoperative EHS	3.0, 0.71	0.57 (N = 39)
Preoperative IPP-SSC	10.1, 2.76	
Postoperative IPP-SSC	2.0, 1.6	<0.0001 (N = 39)

EHS = Erection Hardness Score

## Discussion

### Nesbit vs. Plication Techniques

Previous series of the original Nesbit technique shows good functional results combined with low complication rates [13]. However, certain problems with the Nesbit procedure are described. Popken et al. reported that postoperative hematoma can be associated with tunical excision [14]. Possible overcorrection was discussed by Rolle et al. [15]. On the other hand, several advantages of plication techniques have been propagated, e.g., being a simpler procedure, causing less postoperative bleeding and erectile dysfunction and avoidance of overcorrection [12]. Nevertheless, in an overview of the literature, the postoperative recurrence rate after plication surgery ranges between 0% and 57%, whereas failure rates for the Nesbit procedure are reported to be not higher than 18% [16].


### Incision vs. Excision of Tunica Albuginea

Van der Horst et al. described the technique of tunical plication with horizontal incisions [17],

which was introduced by Baskin and Duckett [18]. Arguing that controlled scar formation induced by the incisions can strengthen tunical plications, the authors reported a lowered recurrence rate of 18%. Similar to van der Horst et al., we also intend to avoid excision of the tunica albuginea but, at the same time, to increase tensile strength as compared with simple plication techniques. So making elliptical incisions without excisions led us to a first version of the underlap technique. The correction is achieved by closing the tunica albuginea over the elliptical incisions. We then proceeded from elliptical to U-shaped incisions to increase tensile strength and, at the same time, to preserve intraoperative adaptability. Also, the perfusion of the U-shaped underlaps might be better compared with the ellipsoid underlaps. In this series, U-shaped incisions were used in all the patients. The two versions of the underlap technique are shown in Figure 3.

### Characteristics of the Tunica Underlap Technique

Significant relapses (deviation > 15 degrees) occurred just in 6% of our patients. This supports the theory that plications with high tensile strength can be achieved by forming double layers of tunica albuginea by means of the underlap technique. Postoperative hematomas were seen in 8% of our patients. We conclude that the underlaps lead to a solid and tight closure of the defects. Avoiding excision of the tunica albuginea might reduce invasiveness. Major complications that required surgical revision occurred only in 4%. Since no tunical tissue was removed, overcorrection, undercorrection, and also torsion could easily be adapted intraoperatively. In our series, postoperative correction of the curvature was 100%. Of the patients, 13% reported some impairment of erectile function by the therapy (13% some, 87% not at all), although the EHS remained constant preoperatively and postoperatively. A possible explanation might be that patients tend to attribute impaired erectile function to the therapy even if erectile function remains constant. It is remarkable to note that there were no complaints of worsening ED in the CPD subgroup compared

**Figure 3** Modified Nesbit technique without excision of tunica albuginea: elliptical vs. U-shaped underlaps.



with 13% overall. One can conclude that the complaint of worsening ED in the IPP subgroup might have its reason in the underlying disease rather than the surgery at least to some extent. The IPP-SSC was decreased in a highly significant way. This suggests that penile deviation was the single most important complaint of the operated patients. Shortening of the penis was reported by 78% (65% some, 13% medium), but did not affect the high satisfaction rate of 87% (72% very strong, 15% strong). Since shortening is inherent to all kinds of Nesbit procedures, detailed informed consent is especially important [19].

### Conclusion

We presented our experience with a new modification of the Nesbit procedure. The technique can be employed in all patients who are candidates for the original Nesbit procedure. With the underlap technique, promising results were achieved, which match those described for the Nesbit procedure by previous authors.

The underlap technique combines features of the Nesbit procedure with features of tunical plication and might bring improvement in three main aspects: adding tensile strength to tunical plations; tighter sealing of tunical defects; and preserving greater intraoperative correctability and avoidance of overcorrection or undercorrection. We think that the underlap technique is a remarkable alternative to the existing modifications of the Nesbit procedure.

### Acknowledgment

I owe gratitude to Prof. Darko Kröpfl from Essen, Germany, for many discussions about the Nesbit procedure and its modifications that inspired this work. Also I would like to thank Dr. Steffen Weiss and Sebastian Löffler from the Chirurgische Klinik München-Bogenhausen for their constant commitment and constructive support for the development of this new surgical technique.

**Corresponding Author:** J. Ullrich Schwarzer, MD, PhD, Andrologie Centrum München, Lortzingstr. 26, München 81241, Germany. Tel: +49 89 820 811 00; Fax: +49 89 820 811 01; E-mail: j.u.schwarzer@gmx.de

*Conflict of Interest:* None.

### References

- 1 Montorsi F, Aidaikan G, Becher E, Giuliano F, Khoury S, Lue TF, Sharlip I, Althof SE, Andersson K-E, Brock G, Broderick

- G, Burnett A, Buvat J, Dean J, Donatucci C, Eardley I, Fugl-Meyer KS, Goldstein I, Hackett G, Hatzichristou D, Hellstrom W, Incrocci L, Jackson G, Kadioglu A, Levine L, Lewis RW, Maggi M, McCabe M, McMahon CG, Montague D, Montorsi P, Mulhall J, Pfau J, Porst H, Ralph D, Rosen R, Rowland D, Sadeghi-Nejad H, Shabsigh R, Stief C, Vardi Y, Wallen K, Wasserman M. Summary of the recommendations on sexual dysfunctions in men. *J Sex Med* 2010;7:3572–88.
- 2 Ralph D, Gonzalez-Cadavid N, Mirone V, Perovic S, Sohn M, Usta M, Levine L. The management of Peyronie's disease: Evidence-based 2010 guidelines. *J Sex Med* 2010;7:2359–74.
- 3 Kadioglu A, Akman T, Sanli O, Gurkan L, Cakan M, Celtik M. Surgical treatment of Peyronie's disease: A critical analysis. *Eur Urol* 2006;50:235–48.
- 4 Hauptmann A, Diemer T, Weidner W. [Peyronie's disease: Diagnostics and therapy]. *Urologe A* 2011;50:609–20.
- 5 Nesbit RM. Congenital curvature of the phallus: Report of three cases with description of corrective operation. *J Urol* 1965;93:230–2.
- 6 Essed E, Schroeder FH. New surgical treatment for Peyronie disease. *Urology* 1985;25:582–7.
- 7 Ebbehøj J, Metz P. New operation for "krummerik" (penile curvature). *Urology* 1985;26:76–8.
- 8 Poulsen J, Kirkeby HJ. Treatment of penile curvature—A retrospective study of 175 patients operated with plication of the tunica albuginea or with the Nesbit procedure. *Br J Urol* 1995;75:370–4.
- 9 Brake M, Keller H, Lamade F, Groh R, Horsch R. [Surgical correction of penile deviation. Nesbit vs. Schroeder-Essed method]. *Urologe A* 1999;38:264–9.
- 10 Schwarzer JU, Mühlen B, Schukai O. Penile corporoplasty using tunica albuginea free graft from proximal corpus cavernosum: A new technique for treatment of penile curvature in Peyronie's disease. *Eur Urol* 2003;44:720–3.
- 11 Mulhall JP, Goldstein I, Bushmakin AG, Cappelleri JC, Hvidsten K. Validation of the Erection Hardness Score. *J Sex Med* 2007;4:1626–34.
- 12 Hsieh J-T, Liu S-P, Chen Y, Chang H-C, Yu H-J, Chen C-H. Correction of congenital penile curvature using modified tunical plication with absorbable sutures: The long-term outcome and patient satisfaction. *Eur Urol* 2007;52:261–6.
- 13 Savoca G, Scieri F, Pietropaolo F, Garaffa G, Belgrano E. Straightening corporoplasty for Peyronie's disease: A review of 218 patients with median follow-up of 89 months. *Eur Urol* 2004;46:610–4; discussion 613–4.
- 14 Popken G, Wetterauer U, Schultze-Seemann W, Deckart AB, Sommerkamp H. A modified corporoplasty for treating congenital penile curvature and reducing the incidence of palpable indurations. *BJU Int* 1999;83:71–5.
- 15 Rolle L, Tamagnone A, Timpano M, Destefanis P, Fiori C, Ceruti C, Fontana D. The Nesbit operation for penile curvature: An easy and effective technical modification. *J Urol* 2005;173:171–3; discussion 173–4.
- 16 Schultheiss D, Meschi MR, Hagemann J, Truss MC, Stief CG, Jonas U. Congenital and acquired penile deviation treated with the Essed plication method. *Eur Urol* 2000;38:167–71.
- 17 van der Horst C, Martinez Portillo FJ, Seif C, Bannowsky A, Bross S, Alken P, Jünemann K-P. [Tunica plication with horizontal incisions of the tunica albuginea in the treatment of congenital penile deviations]. *Aktuelle Urol* 2003;34:478–80.
- 18 Baskin LS, Duckett JW. Dorsal tunica albuginea plication for hypospadias curvature. *J Urol* 1994;151:1668–71.
- 19 Greenfield JM, Lucas S, Levine LA. Factors affecting the loss of length associated with tunica albuginea plication for correction of penile curvature. *J Urol* 2006;175:238–41.